Case Report

DOI: 10.7860/JCDR/2026/89817.24785

Asherman's Syndrome with Prolonged Copper-T Use: A Case Report

Obstetrics and Gynaecology Section

NALINI SHARMA[1], ANUSUYA SARMA[2], KHULAKPAM ARAZ[3]

BY-NC-ND

ABSTRACT

Intrauterine Adhesions (IUAs), or Asherman's syndrome, typically result from damage to the stratum basalis of the endometrium due to intrauterine surgery, infections, or trauma such as curettage. While Copper Intrauterine Devices (IUDs) were traditionally used to prevent recurrence of such adhesions, our case report suggests they may, in rare cases, contribute to their formation. A 40-year-old Para 3 woman presented for the removal of a Copper-T IUD (380 A) inserted 13 years prior (exceeding the 10-year limit). She reported a history of hypomenorrhoea but had no prior history of uterine surgery, curettage, pelvic irradiation, or recurrent infections. Because the IUD thread was missing, a pelvic ultrasound was advised; it showed the Copper IUD in the endometrial cavity but distorted in appearance, with no other abnormality detected. Hence, hysteroscopy was planned. On hysteroscopic evaluation, we found dense, white fibrous scar tissue at the internal os, bridging the walls of the uterine cavity. After ultrasound-guided hysteroscopic adhesiolysis, we successfully identified and removed the embedded Copper-T using graspers. This case highlights that prolonged use of a Copper IUD beyond its stipulated timeframe can lead to the incidental development of IUA, likely due to chronic sterile inflammation and mechanical micro-trauma.

Keywords: Copper, Gynatresia, Hysteroscopy, Intrauterine devices, Oligomenorrhoea, Uterine diseases

CASE REPORT

A 40-year-old woman with three living issues presented to the gynaecology outpatient department for the removal of her Copper IUD in situ, which was inserted 13 years ago, elsewhere (No complaints regarding the same). On elaboration of her menstrual history, she was found to have hypomenorrhoea over the last couple of years; however, her flow was at regular intervals. She revealed no history of any uterine manipulation in the past, including uterine surgery, curettage, pelvic irradiation, or persistent pelvic infections. On per speculum examination, the Copper-T thread was not visible; however, the cervix and vaginal canal were healthy in appearance. A pelvic ultrasound was advised, and it revealed the Copper IUD to be in the endometrial cavity but distorted in appearance, with no other abnormality detected. Given her presentation and findings, she was scheduled for hysteroscopic Copper T removal. A 4.2 mm operative hysteroscope was inserted gradually through the external cervical os; adhesions were noted at the level of the internal os [Table/Fig-1a]. Adhesiolysis was done using hysteroscope scissors. On further negotiation through the internal os, bands of fibrous, white scar tissue were noted bridging the uterine walls, in contrast to the expected smooth, pale pink endometrial lining. We diagnosed intrauterine synechiae and attempted adhesiolysis to reveal the Copper-T buried underneath. But even after adhesiolysis, the Copper-T could not be visualised, as shown in [Table/Fig-1b]. Hence, intraoperative ultrasound assistance was sought to guide the direction of adhesiolysis. The embedded Copper-T was discovered to be in the myometrium after further adhesiolysis under USG guidance, as seen in [Table/Fig-2a]. After visualising the vertical stem of the Copper-T, it was grasped and pulled out from the adhesions. On inspection, all limbs of the Copper IUD were intact, with minimal copper wiring present, as shown in [Table/Fig-2b]. The patient, being from a remote place in North-east India, did not come for follow-up. However, based on the telephonic conversation, the patient had no further complaints.

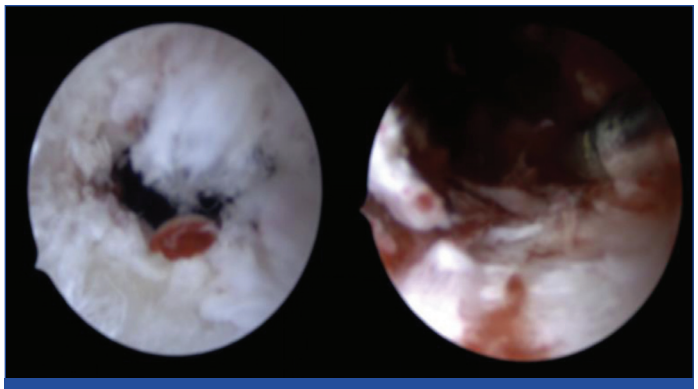

[Table/Fig-1a-b]: (a) Hysteroscopic image of the adhesions at the level of internal os. (b) Image of IUA seen even after adhesiolysis with no evidence of Copper-T.

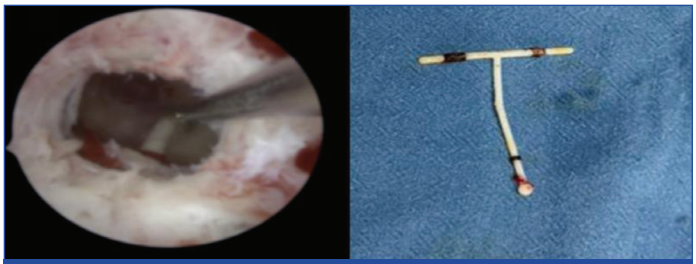

[Table/Fig-2a-b]: a) Embedded Copper-T (vertical stem) seen after USG-guided hysteroscopic adhesiolysis; b) The complete Copper-T seen after removal with minimal copper wiring present around.

DISCUSSION

The IUA, also known as Asherman's syndrome, has been reported a hundred years ago and have been studied since. The prevalence of IUA has a wide range, starting from 1.73% to 40% [1]. In the majority of women, IUA occurs due to damage caused to the stratum basalis of the endometrium by intrauterine manipulation such as curettage, intrauterine infections, operative hysteroscopy, and genital Tuberculosis (TB) [2,3]. IUA presents with menstrual irregularities, pain, and subfertility. The diagnosis of Asherman's syndrome can be made using hysterosalpingography and transvaginal ultrasound, but they have a

high false-positive rate because many polyps and minor fibroids can be misdiagnosed as adhesions; for accurate diagnosis, it is important to use hysteroscopy, which is termed the gold standard [4].

Traditionally, Copper IUDs have been employed for preventing the recurrence of IUAs after adhesiolysis. Levonorgestrel IUDs, inflated Foley catheter bulbs, specialised intrauterine balloons, hyaluronic acid gels, or collagen scaffolds are also used to prevent reformation of uterine synechiae [4].

To date, Abel MK et al., in their case series, described three nulliparous women who were evaluated for endometrial dysfunction without any prior history of uterine manipulation; however, they had a history of levonorgestrel IUD use in all three [2]. Abel MK et al., concluded that a small subset of women may be at risk of developing uterine synechiae and hence have endometrial dysfunction after use of the levonorgestrel IUD [2].

Anjum A et al., in their case report, mentioned a case of a 41-year-old woman presenting with menstrual irregularities and infertility in their OPD, and on evaluation for the same, was found to have Asherman's or Fritsch's syndrome due to a retained fragment of Copper-T in the myometrium [5].

Furthermore, if the IUD is slightly displaced or used for too many years, the plastic frame can cause micro-trauma to the basal layer of the endometrium, which can be the primary cause of adhesion formation, as in this case.

CONCLUSION(S)

While Asherman's syndrome is most commonly an iatrogenic condition following uterine manipulation, this case demonstrates that prolonged Copper IUD use (exceeding 10 years) is a viable, though rare, aetiological factor. Clinicians should remain vigilant when patients with long-term IUDs present with symptoms like hypomenorrhoea, as these may be subtle indicators of underlying uterine synechiae. This case underscores the importance of timely IUD removal and the use of ultrasound-guided hysteroscopy when complications such as embedded devices or dense adhesions are suspected.

REFERENCES

[1] Huang H, Xu B, Cheng C, Xu D. A novel intrauterine stent for prevention of intrauterine adhesions. Ann Transl Med. 2020;8(4):61-61. Doi: 10.21037/atm.2019.12.82.
[2] Abel MK, Wald K, Cedars MI, Noel M. Uterine synechiae after intrauterine device use: A case series. J Assist Reprod Genet. 2021;38(10):2625-29. Doi: 10.1007/s10815-021-02173-6.
[3] Xu P, Xu H, Lu Q, Ling S, Hu E, Song Y, et al. Reproductive outcomes following copper-containing intrauterine device after hysteroscopic lysis for intrauterine adhesions. Exp Ther Med. 2024;27(4):01-06. Doi: 10.3892/etm.2024.12463.
[4] Chibwe E. Case report of post caesarian section Asherman's Syndrome. J Clin Med Images Case Rep. 2022;2(2):1114. Doi: 10.55920/2771-019X/1114.
[5] Anjum A, Tabassum K. A typical case of Asherman Syndrome (Fritsch Syndrome) due to prolonged retained fragment of Cu-T in myometrium. Res Rev J Med. 2019;7(1):10-12.

PARTICULARS OF CONTRIBUTORS:
1. Professor, Department of Obstetrics and Gynaecology, North Eastern Indira Gandhi Regional Institute of Health and Medical Sciences, Shillong, Meghalaya, India.
2. Senior Resident Doctor, Department of Obstetrics and Gynaecology, North eastern Indira Gandhi Regional Institute of Health and Medical Sciences, Shillong, Meghalaya, India.
3. Postgraduate Trainee, Department of Radiology, North Eastern Indira Gandhi Regional Institute of Health and Medical Sciences, Shillong, Meghalaya, India.

NAME, ADDRESS, E-MAIL ID OF THE CORRESPONDING AUTHOR:
Anusuya Sarma,
Quarter B-3-E, Second Floor, NEIGRIHMS Faculty Quarters,
Mawdiangdiang, Shillong-793018, Meghalaya, India.
E-mail: anusuyasarma@gmail.com

PLAGIARISM CHECKING METHODS: [Jain H et al.]
- Plagiarism X-checker: May 07, 2026
- Manual Googling: Sep 16, 2026
- iThenticate Software: Sep 19, 2026 (1%)

ETYMOLOGY: Author Origin

EMENDATIONS: 6

AUTHOR DECLARATION:
- Financial or Other Competing Interests: None
- Was informed consent obtained from the subjects involved in the study? Yes
- For any images presented appropriate consent has been obtained from the subjects. Yes

Date of Submission: **Apr 18, 2026**
Date of Peer Review: **Jul 18, 2026**
Date of Acceptance: **Sep 22, 2026**
Date of Publishing: **Dec 01, 2026**